

Vulvar Dermatoses: Effect of a Synergistic Treatment with a Moisturizing and Healing Product on the Course of the Disease

Filippo Murina¹, Franco Vicariotto²

¹Department of Vulvar Disease, V. Buzzi Hospital, University of Milan, Milan, Italy

²Gynaecology Unit, Casa di Cura "San Pio X" Private Clinic, Milan, Italy

Email: info.filippomurina@tin.it

Received **** 2015

Copyright © 2015 by authors and Scientific Research Publishing Inc.

This work is licensed under the Creative Commons Attribution International License (CC BY).

<http://creativecommons.org/licenses/by/4.0/>



Open Access

Abstract

Background: Vulvar dermatoses are inflammatory disorders of genital skin causing itch, burning, and plaques with overlying excoriation and linear fissures. **Objective:** To assess the effectiveness of a soft foam based on Tiab® system (TF), complex of titanium micro crystals covalently bound with silver ions associated with hyaluronic acid, in the supportive treatment of lichen sclerosus (LS) and lichen simplex chronicus (LSC), the two common vulvar dermatoses. **Method:** 20 patients with the diagnosis of LS or LSC received an 4-week treatment, during which the subjects applied Mometasone furoate in the form 0.1% cream were treated with Mometasone furoate 0.1% cream in combination with TF once a day. Clinical symptoms (itching and burning) and signs (vulvar surface disruption) were documented at baseline and at the end of the four-week treatment. **Results:** There was a significant reduction of symptoms between the basal scores and the symptoms complaints at 4-week treatment. Moreover, a significant reduction of excoriations and linear fissures was observed. **Conclusion:** The present study shows that daily application of TF can be an effective adjunct for the treatment of vulvar dermatosis. The foam had not only a moisturizer action, it may also be associated with a reduction in epithelial disruption in the form of excoriations and fissures.

Keywords

Vular Dermatosi, Lichen Sclerosus, Lichen Simplex Chronicus, Moisturizer

1. Introduction

Vulvar dermatoses are inflammatory conditions responsible for chronic or recurrent itching and burning. Lichen

sclerosus (LS) and lichen simplex chronicus (LSC) are two of the most common vulvar dermatosis [1].

The etiology of LS, the most well recognized vulvar dermatosis, has not yet been adequately explained, but there is increasing evidence that autoimmune mechanisms play a pathogenetic role [2]. The primary lesions are flat, ivory-coloured spots, which may merge together into crinkly thin patches. Affected vulvar skin can be unbearably itchy, burning, and/or sore; sometimes fissuring, blood blisters and erosions appear.

LSC is a lichenification of the vulva caused by persistent itching and scratching. The disease can be considered an atopic disorder in many cases and may arise in normal skin as a result of psychological stress or environmental factors [3]. On examination, LSC presents as erythematous, lichenified plaques with overlying excoriation, and linear fissures may be found at the skin folds. In both the disorders, the area involved may vary from a single small to the entire region of vulva, perineum, and perianus.

The clinical and histological alterations of vulvar dermatoses are responsible for changes in vulvar skin barrier function that enhance the symptoms (dehydration and impaired lipid skin film).

The treatment of all the three disorders should begin with corticosteroid ointments or creams of varying potency [4]. It is also recommended to use emollient creams with the aim of restoring the protective skin barrier [5].

The aim to this study was to assess the effectiveness of a soft foam based on Tiab[®] system (TF), complex of titanium micro crystals covalently bound with silver ions associated with hyaluronic acid, in the supportive treatment of vulvar dermatosis.

Our premise is that TF can acts not only as a moisturizing agent , but it may has a synergistic action with the topical steroid in promoting wound healing and restoration of the protective film skin altered in patients with dermatoses follow.

2. Materials and Methods

A total of 20 of adult female patients with a clinical and/or histological diagnosis of vulvar dermatosis were enrolled in the study.

All of the patients received an 4-week treatment, during which the subjects applied Mometasone furoate in the form 0.1% cream on the affected vulvar surfaces, in combination with a soft foam based on Tiab[®] system (TF), complex of titanium micro crystals covalently bound with silver ions associated with hyaluronic acid used once a day. Mometasone furoate was used in the dose of 1/2 fingertip unit (FTU), *i.e.* the amount of topical drug that is squeezed out from a standard tube on the fingertip of an adult (that is about 0.5 g of topical steroid). Clinical symptoms and signs of the enrolled patients were documented at baseline and at the end of the four-week treatment. Subjective evaluation of the following two symptoms, itching and burning was obtained by interview using a 4-point intensity scale (0 = none, 1 = mild, 2 = moderate and 3 = severe).

The appearance of vulvar surface regarding the excoriations and linear fissures if presents, was considered as a secondary outcome. Grading of vulvar surface disruption was quantified using a four-point scoring system (0 = no lesions, 1 = decreased > 50%; 2 = decreased < 50%; 3 = unchanged).

The signs and symptoms were classified before and after 30 days of treatment.

The EPI-INFO version 6.0 (Centers for Disease Control and Prevention, Atlanta, GA) was used for all statistical analyses. Descriptive statistical analyses (means, standard deviations, and percentages) were performed using the Student t test. Differences were considered significant at $p \geq 0.05$.

3. Results

The characteristics of the study population are summarized in **Table 1**. The symptoms at the first consult were itching and burning in 19 (95%), 11 (55%) women respectively. In terms of the subjective outcome, as reported by the patients (itching and burning) there was a significant reduction of symptoms between the basal scores and the symptoms complaints at 4-week treatment (**Figure 1**). Moreover we observed a significant reduction of excoriations and linear fissures after the treatment. During the entire study no drop out related to the topical treatments was observed; only two patients experienced a mild transient burning after TF application.

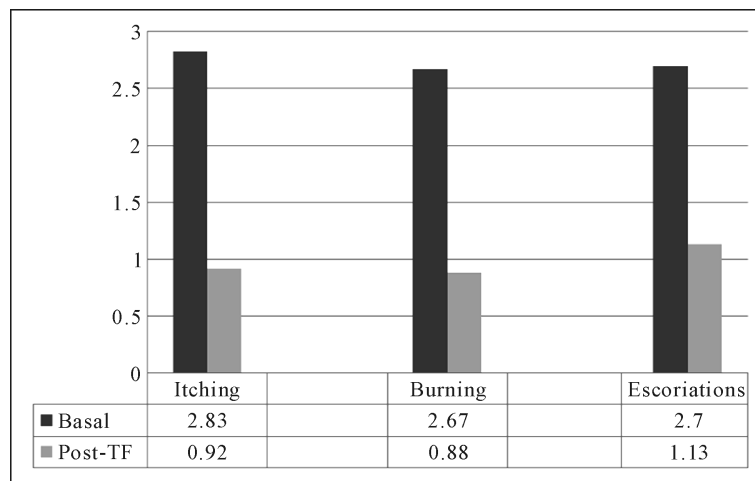
4. Discussion

Currently topical application of a potent corticosteroid cream is the medical treatment of choice of vulvar der-

Table 1. Personal and baseline characteristics of the subjects.

Variable	Data
Age (years)	59.4 (12.66)
Duration of symptoms (months)	18.4 (22.22)
Diagnosis (numbers)	11 (LS) - 9 (LSC)
Itching*	2.40 (0.83)
Burning*	1.75 (0.85)

Data are presented as mean value \pm standard deviation. *Score 0 - 3 (0 = none, 1 = mild, 2 = moderate and 3 = severe). LS = lichen sclerosus; LSC = lichen symplex.



Score 0 - 3 (0 = none, 1 = mild, 2 = moderate and 3 = severe).
Means p value: itching = 0.001, burning = 0.05, escoriations = 0.03.

Figure 1. Symptoms after treatment.

matosis. However, this therapy is not curative, vulvar dermatosis runs a relapsing course, and most women continue to have flares and report pruritus.

In addition, frequently erosions and tender fissures in the labial sulci and perianal area occur.

The present study shows that daily application of TF can be an effective adjunct for the treatment of vulvar dermatosis. LS and LSC are the most common vulvar inflammatory dermatosis.

LS is a chronic inflammatory disease with considerable impact on health-related quality of life.

The cause of lichen sclerosus is unknown, but there is a strong association with autoimmune diseases. Between 21.5% and 34% of those with LS have an associated autoimmune disease [2]. LSC, as an eczematous disease, is characterized by the standard morphology of eczematous disease. Many triggers initiate vulvar pruritus and the subsequently developing LSC. These include environmental factors or topical allergens [1].

Once the itch-scratch cycle has started, LSy takes on a life of its own, regardless of whether or not the triggers remain in place. Crusts almost always contains bacteria.

The typical lesions are porcelain-white papules and plaques with follicular delling and hyperkeratosis are common in both dermatoses. Epithelial disruption in the form of escoriations, weeping, and crusting is present initially; lichenification and poorly marginated, red and white plaques coexist. Escoriations, due to scratching, are superimposed on the underlying inflamed plaques and they may be superficial or deep. Lichenification, on the other hand, is the protective thickening of the skin due to rubbing. In some instances this thickened tissue loses flexibility, in wich case linear fissures develop. The distribution of vulvar dermatoses is usually most prominent over the labia majora but involvement of the labia minora, perineal and perianal area is not uncommon. The barrier function of vulvar skin is substantially weaker than at other anatomical sites; moisture, friction, urine, and vaginal discharge all contribute to vulvar irritation by weakening barrier. function, and these factors

can be exacerbated in patients with vulvar dermatosis where the integrity of vulvar barrier is damaged. Secondary infection may be manifested by pustules, crusting, and fissuring.

Corticosteroids represent the most potent and appropriate agents for the reduction of inflammation.

Mometasone furoate 0.1% ointment has been successfully proposed as an alternative to the standard Clobetasol regimen for LS not only for its efficacy but also for its ability to minimize the side effects associated with the use of more potent corticosteroids [6] [7]. Results of present study confirm the efficacy of MMF 0.1% in a short protocol regimen for the treatment for vulval dermatoses [8]. Inflammation is always present in vulvar dermatosis as results of immunological process. It is associated with the release of cytokines that may have irritating properties. It was demonstrated that topical emollients such as petrolatum, A and D ointment or Aquaphors decrease friction, increase hydration, and may be soothing to the patient with vulvar dermatoses [5].

The epidermal barrier layer is located at the outermost aspect of the epidermis just under the stratum corneum. An intact barrier layer protects the sensory nerve endings, which terminate within the epidermis. This barrier layers fails to function when fingernails disrupt it and when epidermal inflammation forcefully separates the epidermal cells.

Improvement of barrier layer function leads to the restoration of a physiological environment for the nerve endings and it can be accomplished most quickly through the use of soaks. The additional application of a moisturizer seemed to be very important for decreasing recurrences in patients affected by vulvar dermatoses.

In our study we observed that the a soft foam based on Tiab[®] system had not only a moisturizer action, it accelerates normalization of the hydrolipidic film, a natural protective barrier for the skin that helps retain moisture and maintain the skin's natural suppleness, and it may also be associated with a reduction in epithelial disruption in the form of excoriations and fissures. In fact the foam formulation creates a protective barrier and it promotes normal scarring and healing through the creation of a favorable microenvironment to the cellular tissue repair [9]. In addition the foam based on Tiab[®] system has a reservoir effect for lengthy maintenance of active ingredient in vulvar surface.

This involves a prolonged efficacy of the product and the silver ions are able to interact with the functional groups of microorganisms cell membranes. The innovative patented formula has a high bactericide power combined with a healing action.

The new foam exists as a liquid pressurized in an aluminum can with a hydrocarbon propellant (propane/ butane), which upon valve actuation forms a foam lattice Patients find foams less dense and therefore generally easier to apply to and spread on the skin surface.

This may have important clinical implications, especially if the diseased area is inflamed and overly sensitive to mechanical shearing forces. In addition, because the new foam leaves little or no residue after application, patients find the vehicle cosmetically attractive compared with the "greasy" sensation often experienced after the use of ointments.

5. Conclusion

Corticosteroids represent the most appropriate agents for the reduction of symptom and sign of vulvar dermatoses and the association of a new generation foam based on Tiab[®] system enhance their efficacy and providing a concomitant emolience and reduction in epithelial disruption in the form of excoriations and fissures.

References

- [1] Moyal-Barracco, M. and Wendling, J. (2014) Vulvar Dermatitis. *Clinical Obstetrics & Gynaecology*, **28**, 946-958. <http://dx.doi.org/10.1016/j.bpobgyn.2014.07.005>
- [2] Oyama, N., Chan, I., Neill, S.M., *et al.* (2003) Autoantibodies to Extracellular Matrix Protein 1 in Lichen Sclerosus. *Lancet*, **362**, 118Y23.
- [3] Lynch, P.J. (2004) Lichen Simplex Chronicus (Atopic/Neurodermatitis) of the Anogenital Region. *Dermatology and Therapy*, **17**, 8-19.
- [4] Edwards, S., Bates, C., Lewis, F., Sethi, G. and Grover, D. (2014) 2014 UK National Guideline on the Management of Vulval Conditions. *International Journal of STD & AIDS*. <http://dx.doi.org/10.1177/0956462414554271>
- [5] Simonart, T., Lahaye, M. and Simonart, J.M. (2008) Vulvar Lichen Sclerosus: Effect of Maintenance Treatment with a Moisturizer on the Course of the Disease. *Menopause*, **15**, 74Y7.
- [6] Neill, SM., Lewis, F.M., Tatnall, F.M. and Cox, N.H., British Association of Dermatologists (2010) British Associa-

- tion of Dermatologists' Guidelines for the Management of Lichen Sclerosus 2010. *British Journal of Dermatology*, **163**, 672Y82.
- [7] Virgili, A., Corazza, M., Minghetti, S. and Borghi, A. (2015) Growing Evidence for Topical Mometasone Fuoroate in the Treatment of Vulvar Lichen Sclerosus. *Maturitas*, **80**, 113-115. <http://dx.doi.org/10.1016/j.maturitas.2014.09.005>
- [8] Murina, F., Rehman, S., Di Francesco, S., Mantegazza, V., Felice, R. and Bianco, V. (2015) Vulvar Lichen Sclerosus: A Comparison of the Short-Term Topical Application of Clobetasol Dipropionate 0.05% versus Mometasone Furoate 0.1. *Journal of Lower Genital Tract Disease*, **19**, 149-151. <http://dx.doi.org/10.1097/LGT.0000000000000065>
- [9] Huang, X., Tanojo, H., Lenn, J., Deng, H. and Krochmal, L. (2005) A Novel Foam Vehicle for Delivery of Topical Corticosteroids. *Journal of the American Academy of Dermatology*, **53**, S26-S38. <http://dx.doi.org/10.1016/j.jaad.2005.04.028>